

Right Ovarian Cyst And It's Clinical Significance In Surgery: A Case Report

Dr. Smitaraje D. Wader

Professor, Rachana Sharir Department, KAHER's Shri B.M.K. Ayurved Mahavidyalaya,
Shahapur, Belagavi – 590003, Karnataka, India.

DOI:10.37648/ijrmst.v18i01.009

¹Received: 07 July 2024; Accepted: 07 October 2024; Published: 28 October 2024

ABSTRACT

Ovaries are paired female internal reproductive organs located in ovarian fossa. Each ovary is oval-shaped, measuring approximately 4 cm in length and 2 cm in width. One end is oriented medially toward the uterus, while the other points laterally toward the fimbriated end of the uterine tube. Each ovary is attached to the broad ligament by mesovarium, a posterior extension of the broad ligament which conveys the ovarian vessels.

Ovaries are the sites for oogenesis. Ovarian cysts often develop due to normal hormonal changes in puberty or during menopause. Follicular cysts are common and originate in unruptured graafian follicles; rarely exceed 1.5cm in diameter. Luteal cysts are formed in the corpus luteum & they rarely exceed 3cm in diameter. Fluid retention prevents the corpus luteum from becoming fibrosed. While most cysts resolve on their own, some may persist. It is estimated that approximately 10 out of 100 women develop ovarian cysts.

Ovarian cysts are leading cause of infertility. The majority of ovarian cysts are benign, particularly those presenting with acute pain, pain may occur because of cyst torsion, cyst rupture, or bleeding into the cyst. Management depends on the presenting clinical situation and may requires urgent surgical intervention.

Keywords: *Ovary; Ovarian Cyst; Surgery*

INTRODUCTION

Ovaries are the paired female located in Ovarian fossa on lateral pelvic wall bounded anteriorly by the obliterated artery and posteriorly by the ureter & internal iliac artery. Approx.4cm long and 2 cm broad. Ovaries have smooth surface and greyish pink in color. After puberty the surface becomes uneven & color changes to grey. Ovary is having two poles; one pole is directed towards the uterus and the other towards the fimbriated end of the uterine tube. Each ovary is attached to the broad ligament by mesovarium^{1,2} Ovaries are responsible for the production of estrogen and progesterone and also site for oogenesis^{2,3}. Ovarian cysts often develop due to normal hormonal changes in puberty or during menopause⁴ and are the leading cause of infertility⁵.

AIMS AND OBJECTIVES

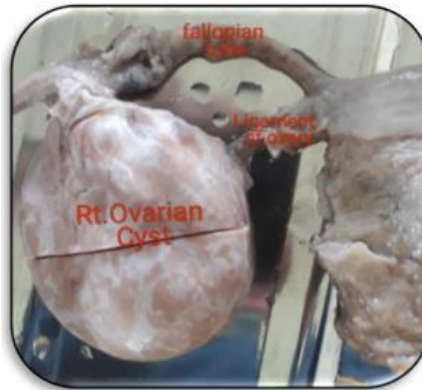
1. Clinical significance of Ovarian cyst in surgery.
2. Evaluation of the incidence of ovarian cysts.

¹ How to cite the article: Wader S.D (October 2024); Right Ovarian Cyst And It's Clinical Significance In Surgery: A Case Report; *International Journal of Research in Medical Sciences and Technology*; Vol 18, 53-56, DOI: <http://doi.org/10.37648/ijrmst.v18i01.009>

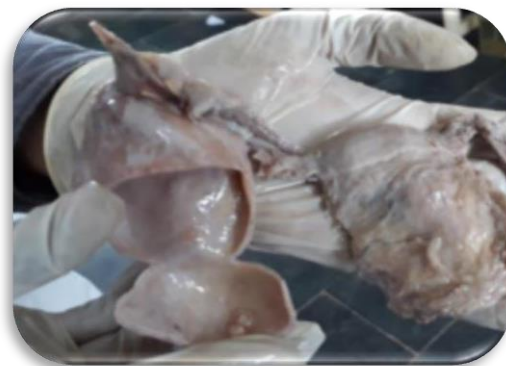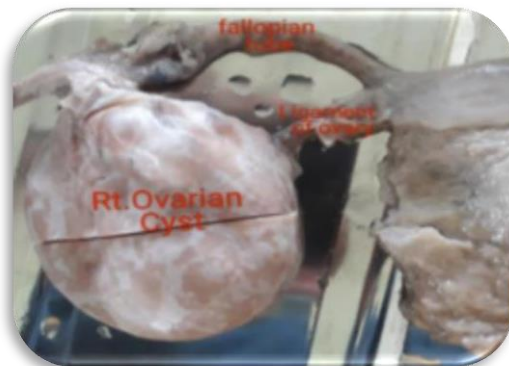
MATERIALS AND METHODS

- Cadaver, dissection instruments, measuring scale.
- The present case was reported in 58 yrs aged female cadaver during routine cadaveric dissection of pelvis by ayurvedic undergraduate students in Department of Rachana Sharira in my previous working institute.
- Literary material is collected from anatomy, gynecology & it's surgical text books, articles & references from internet.
- Method: The dissection of the pelvis was carried out as per Cunningham practical manual.

OBSERVATIONS AND RESULTS



- The uterus appeared normal in both shape and size.
- A right ovarian cyst was identified in the right iliac fossa.
- It was a single ovarian cyst, measuring approximately 7.2 cm in length and 4.2 cm in width.
- The surface of the cyst was smooth, and its consistency was soft.
- The cyst was attached to the right fallopian tube and connected to the uterus via the right ovarian ligament.



DISCUSSION

Ovarian cysts can be categorized as follows:

- **Polycystic Ovarian Syndrome (PCOS)**
- **Functional Ovarian Cysts**
 - Follicular Cysts
 - Corpus Luteum Cysts
- **Pathological Ovarian Cysts**
 - Dermoid Cysts
 - Cystadenomas, etc.

In PCOS ovaries shows many, small fluid filled sacs i.e. cysts^{7,8}. Follicular cysts are common and originate in unruptured graafian follicles and rarely exceed 1.5cm in diameter. Luteal cysts are formed in the corpus luteum and rarely exceed 3cm in diameter^{4,5}. Fluid in luteal cyst is retained and the corpus luteum cannot become fibrosed.

Common Signs And Symptoms Of Ovarian Cysts⁵

- Abdominal swelling.
- Painful bowel movements.
- Pelvic pain before or during the menstrual cycle.
- Painful intercourse
- Pain in lower back or thigh
- Breast tenderness

When a cyst ruptures from the ovary,

- Severe or sharp pain in lower abdomen in one side,
- Fever,
- Faintness or dizziness,
- Rapid breathing.

Majority of ovarian cysts are benign, particularly those presenting with acute pain. Management depends on the presenting clinical situation.^{5,6}

CONCLUSION

- In women of reproductive age most ovarian cysts are functional and benign and do not require surgical intervention.
- Though acute pain will be seen with benign ovarian cysts, it may occur because of cyst torsion, cyst rupture, or bleeding into the cyst which are considered gynecological emergencies.
- So, prompt diagnosis and treating them is essential to avoid high morbidity and mortality. Ovarian torsion requires urgent surgical intervention to relieve the pain and treat the cyst. It shows the clinical significance of surgery in ovarian cyst.

REFERENCES

1. B D Chaurasia's Human Anatomy Vol 2 Sixth edition 382-386
2. Holland Tom, Sayasneh Ahmad. Gray's surgical anatomy. Elsevier;
3. Drake RL, Vogl W, Mitchell AWM, Gray H. Gray's anatomy for students.3rd ed. Philadelphia: Churchill Livingstone/Elsevier; 2015.
4. Magowan B, Owen P, Thomson AJ. Clinical obstetrics & gynecology. Elsevier; 2019.
5. Information NC for B, Pike USNL of M 8600 R, MD B, Usa 20894. Ovarian cysts: Overview [Internet]. www.ncbi.nlm.nih.gov. Institute for Quality and Efficiency in Health Care (IQWiG); 2019. Available from: <https://www.ncbi.nlm.nih.gov/books/NBK539572/>
6. Amesse LS. Ovarian Cystectomy: Overview, Epidemiology, Indications [Internet]. Medscape.com. Medscape; 2023 [cited 2024 Oct 18]. Available from <https://emedicine.medscape.com/article/1848505-overview#showall>.
7. Shaw R w, Luesley D, Monga A. Gynaecology [Internet]. Fourth. Churchill Livingstone: ELSEVIER; 2011. Available from: www.elsevierhealth.com page no.252-264,668- 677.
8. Dutta DC, Hiralal Konar. DC Dutta's textbook of gynecology: including contraception. New Delhi: Jaypee Brothers Medical Publishers (P) Ltd;2014.
9. Konar H. DC Dutta's Textbook of Obstetrics.8th Edition, New Delhi, Jaypee Brothers Medical Publishers Pvt Limited; 2020.p433.
10. Konar H. DC Dutta's Textbook of Obstetrics.8th Edition, New Delhi, Jaypee Brothers Medical Publishers Pvt Limited; 2020.p422.